

# Combined Treatment of Wrist and Trapeziometacarpal Joint Arthritis

Thomas Waitzenegger, MD<sup>1</sup> Caroline Leclercq, MD<sup>2</sup> Emmanuel Masméjean, MD, PhD<sup>3</sup>  
Hubert Lenoir, MD<sup>1</sup> Amir Harir, MD<sup>4</sup> Bertrand Coulet, MD, PhD<sup>1</sup> Michel Chammas, MD, PhD<sup>1</sup>

<sup>1</sup> Hand and upper limb surgery department, Lapeyronie Hospital, CHRU Montpellier, France

<sup>2</sup> Hand Institut, Clinique Jouvenet, Paris, France

<sup>3</sup> Hand and upper limb surgery department, Georges Pompidou European Hospital, Paris, France

<sup>4</sup> Hand and upper limb surgery department, St Antoine Hospital, Paris, France

**Address for correspondence** Thomas Waitzenegger, MD, Service de chirurgie de la main, du membre supérieur et des nerfs périphériques, 371 Avenue du Doyen Gaston Giraud, 34295 Montpellier, Cedex 5, France (e-mail: t.waitzenegger@gmail.com).

J Wrist Surg 2015;4:301–306.

## Abstract

**Background** Combined thumb basal and wrist joint arthritis (excluding scaphotrapeziotrapezoid arthritis) is rare considering the frequency of arthritis of either joint alone. Combined surgical treatment has never been described in the literature. Furthermore, the scaphoidectomy common to all interventions for Watson stage 2 or 3 wrist arthritis theoretically makes it impossible to perform a trapeziectomy for thumb basal joint arthritis.

**Question/Purpose** The aim of this study was to present and analyze the results of two types of surgical treatment when both wrist and thumb arthritis was present.

**Materials and Methods** Our retrospective series included 11 patients suffering from Eaton Stage III thumb basal joint arthritis and scapholunate advanced collapse (SLAC) II and III-type wrist arthritis. Five patients (group A) underwent trapeziectomy and palliative surgery for their wrist with conservation of the distal pole of the scaphoid (one proximal row carpectomy [PRC] and four four-corner fusions), and six (group B) patients had a trapeziometacarpal arthroplasty either with PRC (two cases) or four-corner arthrodesis (four cases) including total scaphoidectomy.

**Results** The mean follow-up was 57 months. The overall visual analog scale (VAS) score for pain was 1.5 at rest, with no difference between the trapeziectomy and arthroplasty groups. The average Kapandji score was 9.3 (9 in group A and 9.5 in group B). The flexion/extension range of motion for the wrist was 64° following four-corner arthrodesis and 75° following PRC. Only one case of algodystrophy was observed. The radiological analysis revealed no complications.

**Discussion** This study shows that thumb basal joint arthritis and SLAC type wrist arthritis may be treated by combined treatment during the same intervention without any complications. The results of palliative surgery for the wrist, either with trapeziectomy or with a trapeziometacarpal arthroplasty, are comparable. With a trapeziectomy, the distal pole of the scaphoid must be fused to the capitate to help stabilize the thumb column.

**Level of Evidence** Level IV.

## Keywords

- ▶ arthritis
- ▶ arthroplasty
- ▶ combined treatment
- ▶ trapeziectomy
- ▶ trapeziometacarpal joint
- ▶ wrist

Combined arthritis of the trapeziometacarpal (TMC) joint and the wrist is a rare pathology. This combination is not described in the literature. Although these two pathologies each have their own relatively well-codified treatment, no therapeutic management for combined arthritis of the TMC joint and the wrist has ever been described.

TMC joint arthritis is a common pathology. The therapeutic arsenal ranges from medical and orthotic treatment to surgical treatment with a trapeziectomy, arthroplasty, or TMC arthrodesis.

Wrist arthritis has several origins, with posttraumatic causes at the top of the list, such as scaphoid nonunion advanced collapse (SNAC wrist) and scapholunate advanced collapse (SLAC wrist), metabolic diseases such as chondrocalcinosis and gout, and lastly osteonecrosis of the lunate or Kienböck disease. The main treatments according to the stage of arthritis are partial and total wrist fusion, proximal row carpectomy (PRC), and wrist denervation.

Various combinations may therefore be envisaged to treat these cases of combined arthritis (→Fig. 1). Following a trapeziectomy, removing the scaphoid in association with either a partial wrist arthrodesis or PRC creates the problem of how to prevent subsidence of the thumb metacarpal to maintain the height of the thumb column and its stability.

The aim of this work was to present and evaluate combined treatment in patients with wrist and TMC joint arthritis by comparing the results following an implant arthroplasty as compared with a trapeziectomy and ligament suspension arthroplasty.

## Materials and Methods

### Patients

This retrospective series included 11 patients with combined wrist and TMC joint arthritis who were operated on in three academic hospitals that specialized in hand surgery from

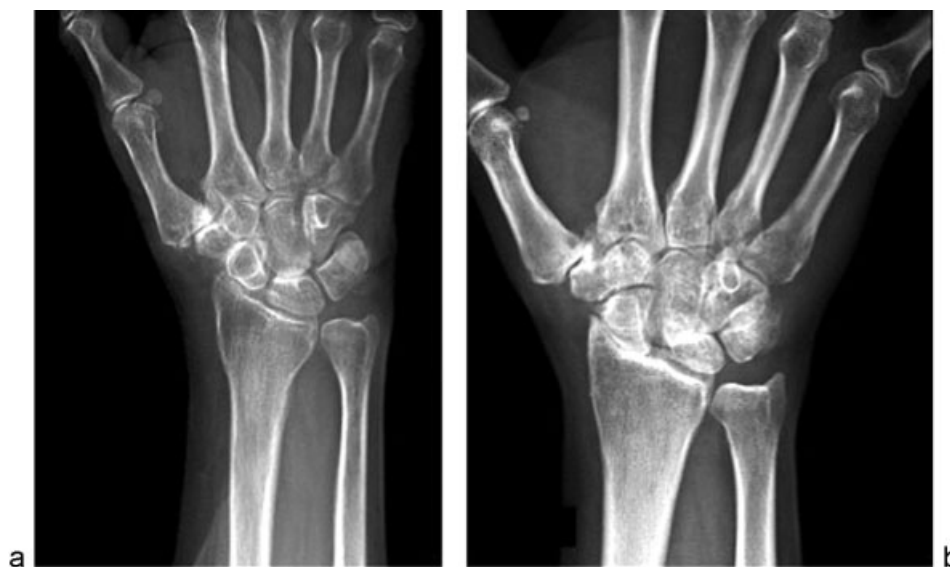2003 to 2011. The same surgeon who was not involved with the original surgery independently reviewed the 11 patients.

The series included 10 female patients and one male patient. The mean age at the time of surgery was 67 years (range, 51–79 years). Nine of the 11 patients were retired. The dominant side was operated on in 7/11 (64%) of cases. The patients were divided in two groups based upon the type of thumb procedure. Group A consisted of five patients who underwent a trapeziectomy combined with a suspension ligamentoplasty using the abductor pollicis longus (APL). Group B consisted of six patients who underwent a TMC implant arthroplasty. The main reason for consultation was pain in two different sites: the wrist and base of the thumb. The diagnosis was determined by a physical exam revealing pain during wrist and basal thumb motion and direct palpation. Radiographs were taken of the wrist and the thumb, including computed tomographic (CT) wrist arthrography. All patients with thumb basal joint arthritis were treated with painkillers and a forearm-based thumb spica splint due to the concomitant wrist arthritis for over 9 months (mean 13 months, range 9–17 months)

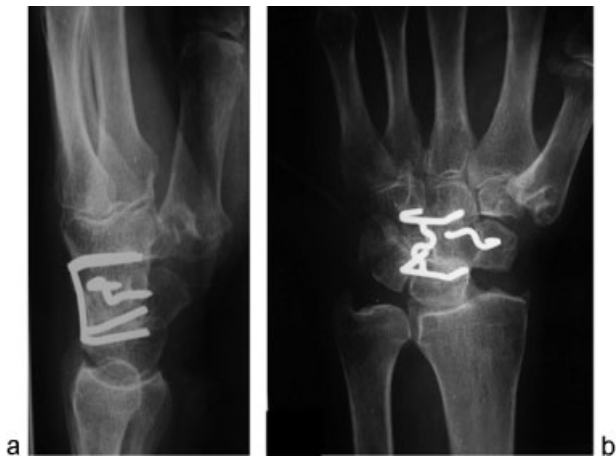### Surgical Technique

The procedure was performed by a senior surgeon in all cases. Each procedure was performed under tourniquet control and regional anesthesia.

A Gedda-Moberg approach was done in all cases. This approach follows the line of the abductor pollicis longus (APL), which is retracted palmarly and the terminal branches of the superficial radial sensory nerve are identified. Then the thenar muscles are reflected subperiosteally. The carpometacarpal (CMC) joint capsule is identified and incised. With this anterolateral approach, it is easier to remove the distal scaphoid. The TMC joint arthritis was treated with a total trapeziectomy combined with a suspension ligamentoplasty using the APL in five cases (group A) and a TMC implant



**Fig. 1** Preoperative X-ray images: (a) SLAC III and (b) Stage 2 thumb basal joint arthritis.



**Fig. 2** (a,b) Trapeziectomy and four-corner arthrodesis (arthrodesis of the distal pole of the scaphoid to the capitate) + styloidectomy.

arthroplasty (Maïa, Groupe Lépine, Genay, France) in six cases (group B). At the same time a posterior interosseous nerve (PIN) resection was performed.

In group A (→Figs. 2, 3), four cases of partial wrist fusion (four- or three-corner arthrodesis) and one case of PRC were performed. In these patients the distal pole of the scaphoid was conserved by fusing it to the capitate, since we believe that a suspension ligamentoplasty by itself would not prevent subsidence, and a radial styloidectomy was performed to avoid impingement between the radial styloid and distal scaphoid fragment. In group B (→Figs. 4, 5), four cases of partial wrist fusion (four- or three-corner arthrodesis) and two cases of PRC were performed. Postoperatively the patients were immobilized in a thumb spica

splint for 6 weeks. Protected thumb motion was allowed at 4 weeks in group A and at 10 days for group B. The mean follow-up was 57 months (range 42–69 months).

The outcome at the follow-up examination consisted of the following components: We used the visual analog scale (VAS) scores 0 to 10 for pain at rest. We noted the Kapandji score<sup>1</sup> used to measure opposition of the thumb (/10). The contact between the top of the thumb pulp and the other fingers is used to calculate this score thanks to the numbered fingers (→Fig. 6). We also measured grip strength, pinch strength, and wrist motion.

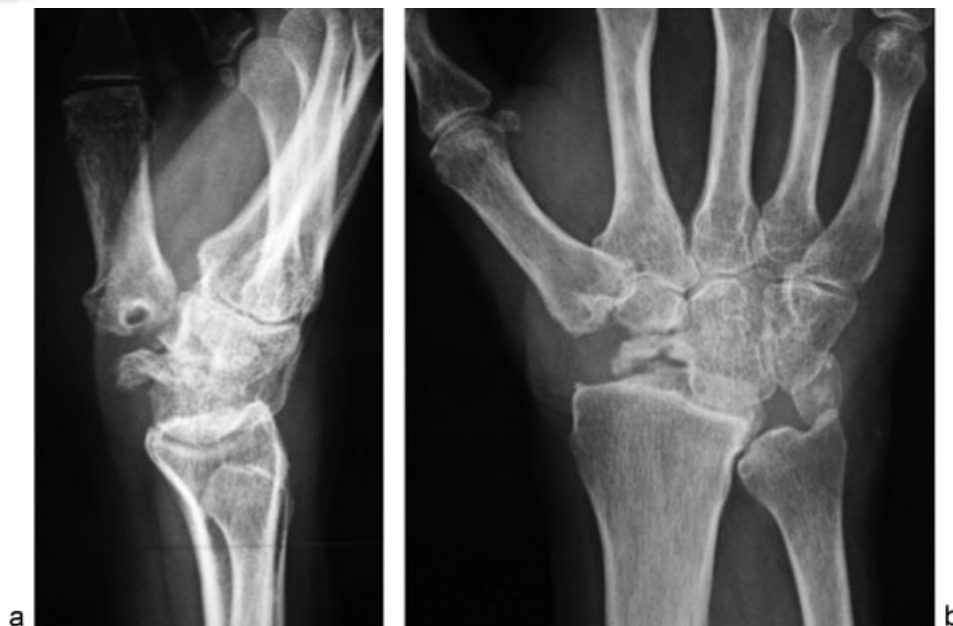The subjective outcome was measured using the Quick Disabilities of the Arm, Shoulder, and Hand<sup>2</sup> (QuickDASH) score (in which a score of 0 means no disability and a score of 100 means complete disability). The Patient-Rated Wrist Evaluation<sup>3</sup> (PRWE) was also used to evaluate function and pain, with the worst being a score of 150.

Preoperative and final follow-up radiographs (posteroanterior and lateral projections) were available for all patients. At the final follow-up, we also evaluated radiocarpal joint arthritic changes, ulnar translocation of the wrist, styloscapoid impingement (pain with radial deviation), and complications such as loosening or prosthetic subluxation. Complications were recorded for each patient.

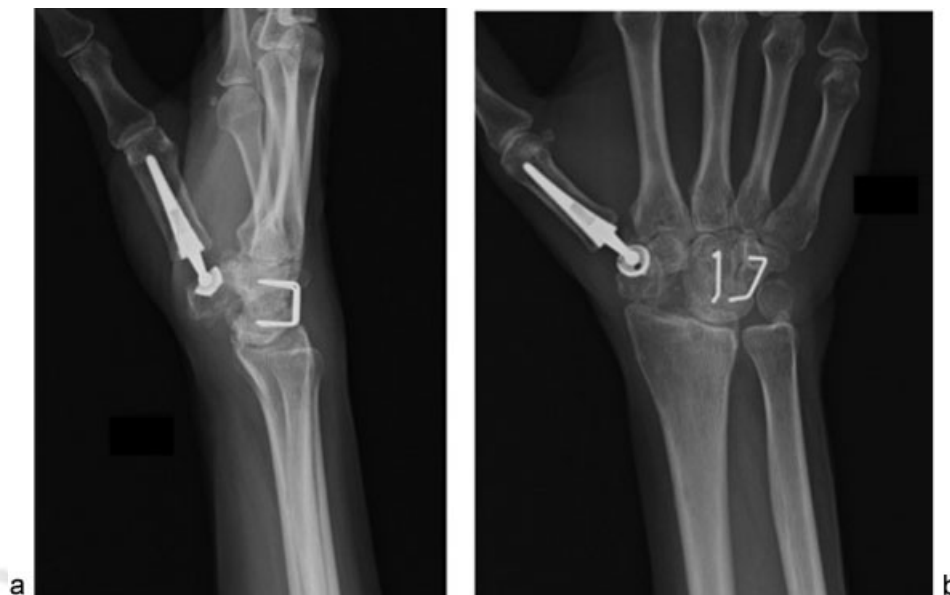
## Results

### Clinical

There was one case of Eaton<sup>4</sup> stage 2 and 10 cases of Eaton stage 3 thumb basilar joint arthritis. In this classification, stage I comprises normal articular surfaces without joint space narrowing or sclerosis. There is less than one-third subluxation of the metacarpal base. Stage II reveals mild joint space narrowing, mild sclerosis, or osteophytes < 2



**Fig. 3** (a,b) Trapeziectomy and PRC with arthrodesis of the distal pole of the scaphoid at the capitate plus styloidectomy.



**Fig. 4** (a,b) Trapeziometacarpal arthroplasty and 3-corner arthrodesis.

mm in diameter. Instability is evident on stress views with > one-third subluxation. The scaphotrapeziotrapezoid (STT) joint is normal. In stage III there is significant joint space narrowing, subchondral sclerosis, and peripheral osteophytes > 2 mm in diameter but a normal STT joint. In stage IV there is pantrapezial OA with narrowing, sclerosis, and osteophytes involving both the TMC and STT joints.

All the patients had SLAC-type wrist arthritis.<sup>5</sup> This scapholunate advanced collapse begins by degenerative change between the radial styloid and scaphoid (stage I). This progresses to degeneration of the entire radioscaphoid joint (stage II) and then involvement of the capitulunate joint (stage III) as described by Watson (►Fig. 7).

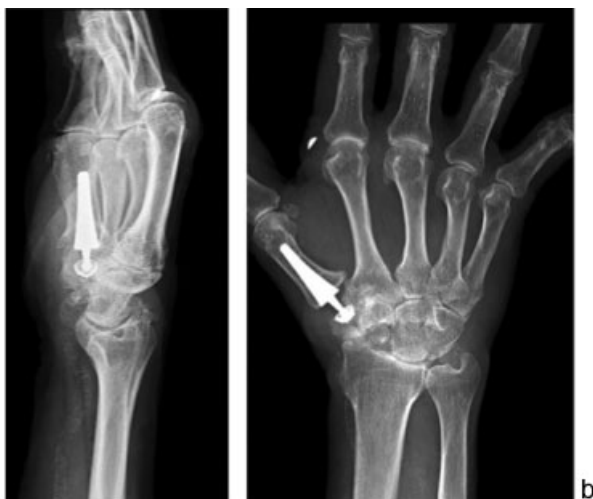In 8/11 patients (73% of cases) this was SLAC III and in 2/11 patients (27% of cases) it was SLAC II (►Fig. 1).

Preoperatively, the mean overall VAS was 7.5 (range, 6–9), with a mean VAS of 7.7 for group A and 7.3 for group B. The mean Kapandji score<sup>1</sup> was 7.3 (7 for group A, 7.5 for group B). The grip strength was 15.6 kgf, and the pinch strength was 3.6 kgf (Table 1). At the last follow-up, we noted a complete disappearance of wrist pain in 6/11 (55% of cases), thumb pain in 8/11 patients (72% of cases), and both in five patients. The overall VAS was 1.5 at rest, with no difference between group A (VAS 1.6) and B (VAS 1.4). The results are summarized in ►Table 1.

No septic complications or paresthesia in the territory of the superficial branches of the radial nerve were noted. However, one case of algodystrophy were noted in group A.

The X-ray analysis showed no loosening for the TMC arthroplasty cases (Group B). There were no arthroplasty dislocations. In group A the arthrodesis between the distal pole of the scaphoid and the capitate was fused in all cases. No ulnar translocation was observed, and there were no cases of styloscapoid impingement. At the last follow-up, radiographs demonstrated radiocarpal arthrosis in one patient, who underwent a four-corner arthrodesis with a TMC arthroplasty.

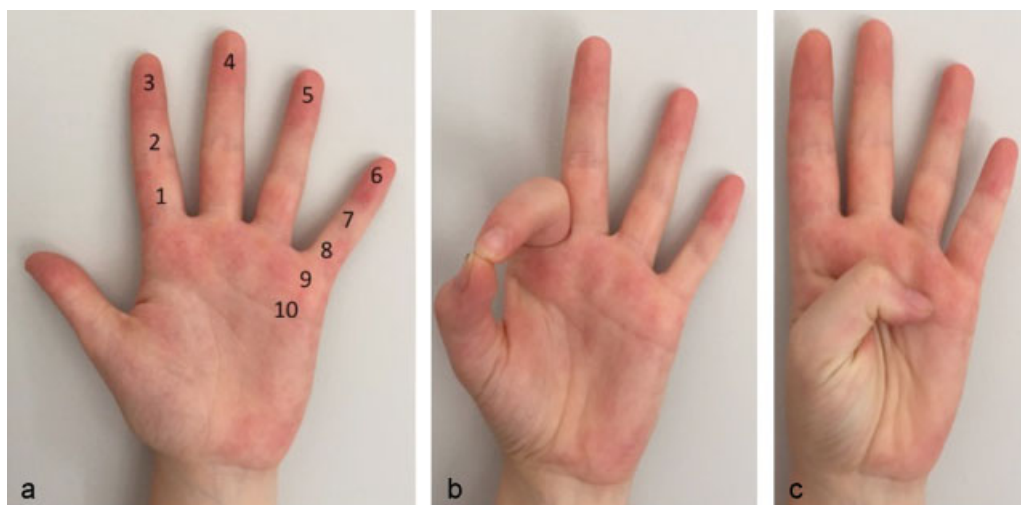
Our institution does not require institutional review board (IRB) approval.



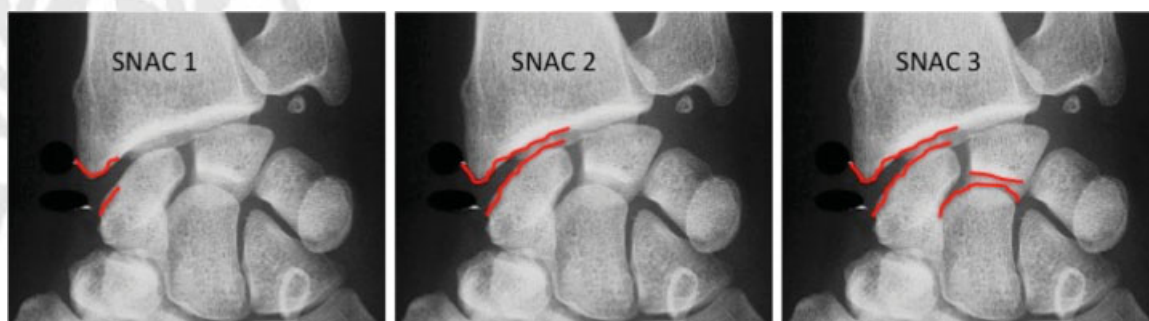**Fig. 5** (a,b) Trapeziometacarpal arthroplasty and PRC.

## Discussion

The main problem remains how to manage combined TMC and wrist joint arthritis during the same surgical procedure. With a total trapeziectomy, a scaphoidectomy performed in the context of partial wrist arthrodesis or PRC poses the problem for conservation of the height of the thumb column and its stability.



**Fig. 6** Kapandji score. (a) Numbered fingers to establish the opposition score. (b) The thumb touches only the middle phalanx of the index, Kapandji score is 2. (c) The thumb touches the distal palmar flexion creases, Kapandji score is 10.



**Fig. 7** SLAC wrist classification.

Our series shows active ranges of motion comparable to those in the literature, with a flexion/extension range of 64° following four-corner arthrodesis and 75° following PRC, but grasp strength is clearly lower compared with the results found in the literature (55% in our series versus 75%). The association of these two arthritic locations easily explains this loss of grasp strength. However, the absence of difference in pinch strength and Kapandji score regarding the trapeziectomy or isolated TMC arthroplasty series makes us think that the treatment of wrist arthritis does not influence the result of treating thumb basal joint arthritis. The influence of preserving the distal pole of the

scaphoid compared with the total scaphoidectomy, whether following PRC or four-corner arthrodesis, was not significant in our series. No difference in terms of pain, active range of motion, or strength was noted at the last follow-up.

Performing a trapeziectomy combined with a four-corner arthrodesis requires the conservation of the distal pole of the scaphoid so that this can be fused with the capitate to avoid a major collapse of the thumb. This may result in styloscapoid impingement, which may result from conserving the distal pole of the scaphoid. This is why we believe it is essential to perform a styloidectomy.

**Table 1** Clinical results

	Preoperative				Postoperative			
	VAS (/10)	Grip Pinch (kgf)	Kapandji score (/10)	DASH PRWE	VAS (/10)	Grip Pinch (kgf)	Kapandji score (/10)	DASH PRWE
Group A (5 cases)	7,7	15,3 3,4	7	51 110	1,6	9 4,2	9	23 41
Group B (6 cases)	7,3	15,9 3,8	7,5	41 114	1,4	9,3 4,9	9,5	21 49

Because of this uncommon association, the number of cases is still limited; therefore a statistical analysis was not performed. Similarly, we could not compare the results of the groups A or B with regards to the base of the thumb because of the small numbers. Although we believe that salvage of the distal scaphoid pole is important, we acknowledge that, because there was no soft tissue interposition and the STT ligaments were removed, preservation of the distal scaphoid may not prevent subsidence nor stabilize the TMC joint in any way.

**Conflict of Interest**

None

**References**

- 1 Kapandji AI. Clinical test of apposition and counter-apposition of the thumb [in French]. *Ann Chir Main* 1986;5:67-73
- 2 Hudak PL, Amadio PC, Bombardier C; The Upper Extremity Collaborative Group (UECG). Development of an upper extremity outcome measure: the DASH (disabilities of the arm, shoulder and hand) [corrected]. *Am J Ind Med* 1996;29(6):602-608
- 3 MacDermid JC. *The Patient-Rated Wrist/Hand Evaluation*. School of Rehabilitation Science, McMaster University; 2009
- 4 Eaton RG, Lane LB, Littler JW, Keyser JJ. Ligament reconstruction for the painful thumb carpometacarpal joint: a long-term assessment. *J Hand Surg Am* 1984;9(5):692-699
- 5 Watson HK, Ballet FL. The SLAC wrist: scapholunate advanced collapse pattern of degenerative arthritis. *J Hand Surg Am* 1984; 9(3):358-365



THIEME